

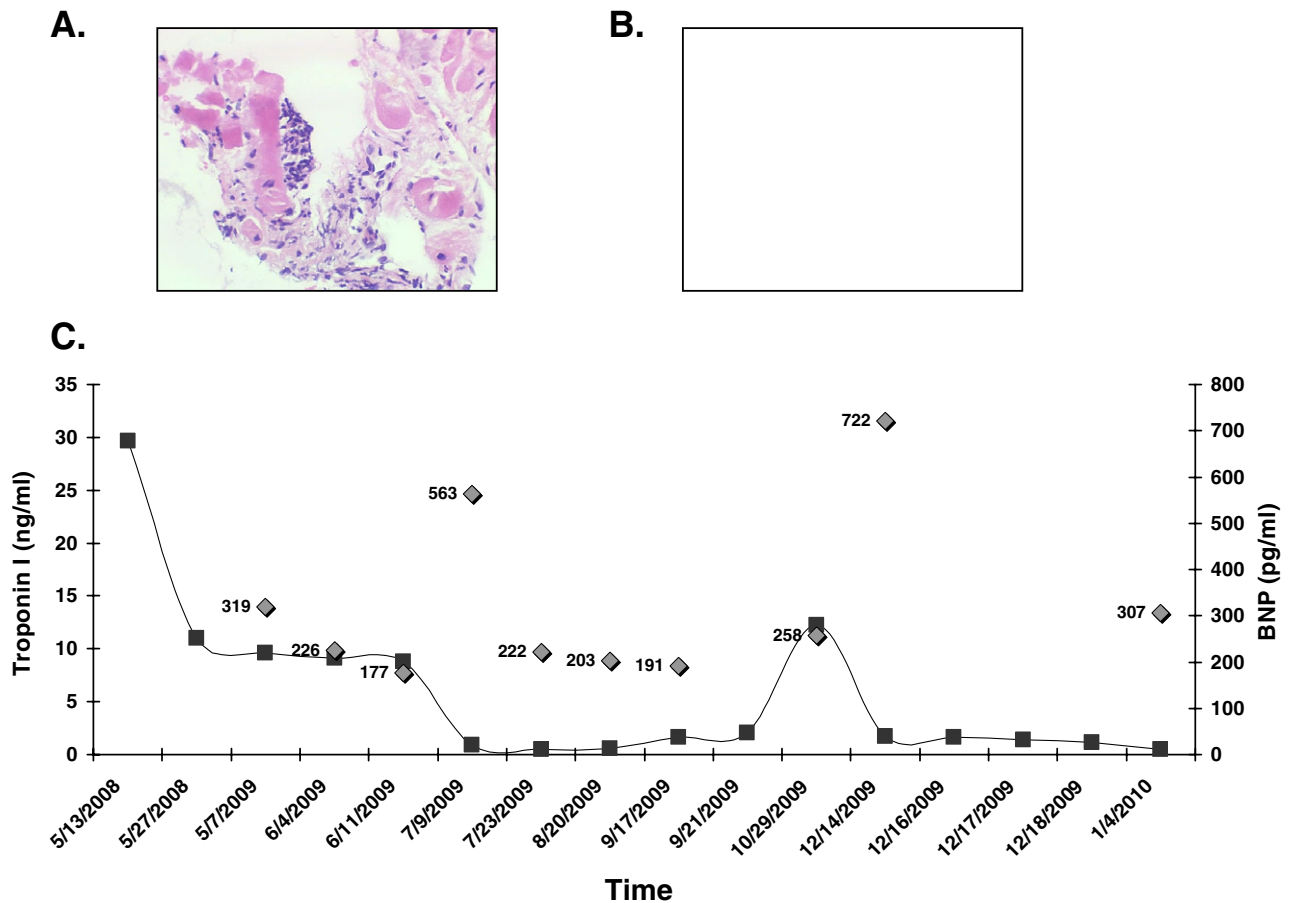Figure 1 Myocardial biopsy specimens show (A) lymphocytic and eosinophilic infiltrate, hematoxylin and eosin stain, original magnification $\times 100$; and (B) resolution of inflammation with interstitial fibrosis during the index admission. Hematoxylin and eosin stain, original magnification $\times 200$. (C) Serial cardiac troponin I and corresponding brain natriuretic peptide (BNP) levels are shown.

Disclosure statement

None of the authors has a financial relationship with a commercial entity that has an interest in the subject of the presented manuscript or other conflicts of interest to disclose.

Rene Quiroz, MD, MPH

*Cardiovascular Section and Evans Department of
Medicine
Boston University School of Medicine
Boston, Massachusetts*

Lija Joseph, MD

*Department of Pathology
Boston Medical Center
Boston, Massachusetts*

Flora Sam, MD

*Cardiovascular Section and Evans Department of
Medicine
Whitaker Cardiovascular Institute
Boston School of Medicine
Boston Medical Center
Boston, Massachusetts*

References

- Cooper LT, Jr. Myocarditis. *N Engl J Med* 2009;360:1526-38.
- Kadota S, Takeuchi Y, Izuhara M, et al. The importance of serial cardiac troponin measurement for evaluating the response to immunosuppressive therapy for myocarditis. *J Cardiol* 2008;52:154-8.
- Giannoni A, Giovannini S, Clerico A. Measurement of circulating concentrations of cardiac troponin I and T in healthy subjects: a tool for monitoring myocardial tissue renewal? *Clin Chem Lab Med* 2009;47:1167-77.
- Feng J, Schaus BJ, Fallavollita JA, Lee TC, Canty JM Jr. Preload induces troponin I degradation independently of myocardial ischemia. *Circulation* 2001;103:2035-7.
- Perna ER, Macin SM, Canella JPC, et al. Ongoing myocardial injury in stable severe heart failure: value of cardiac troponin T monitoring for high-risk patient identification. *Circulation* 2004;110:2376-82.
- Smith SC, Ladenson JH, Mason JW, Jaffe AS. Elevations of Cardiac troponin I associated with myocarditis: experimental and clinical correlates. *Circulation* 1997;95:163-8.

Long-term biventricular support with the heartware implantable continuous flow pump

To the Editor:

Implantation of ventricular assist devices (VADs) for circulatory support requires biventricular assistance in up to 30% of patients.¹ Long-term options include a total artificial

heart, requiring native heart excision, or biventricular VADs (BiVADs) using extracorporeal or implantable displacement pumps. We report an innovative technique for the creation of an implantable BiVAD.

After median sternotomy during cardiopulmonary bypass, a HeartWare HVAD (Framingham, MA) centrifugal pump was implanted into the LV apex, and the outflow graft was connected to the ascending aorta.² The optimal position for the second HeartWare pump as a right ventricular assist device (RVAD) on the free wall of the RV (at the point of maximum distance from the ventricular septum) was determined by transesophageal echocardiography. The inflow cannula was placed in the RV cavity and secured as described for the LVAD, with 2 additional silicone rings (total 5 mm thickness) placed under the fixation ring to lower the part of the inflow cannula protruding into the RV.

The outflow graft, narrowed before surgery from 10 to 5 mm, was sutured to the pulmonary artery (Figure 1). The narrowing was achieved by suturing a 3-cm-long piece of graft with 6-0 Prolene (Ethicon, Sommerville, NJ) 2 cm from the outflow connector over a 5-mm Hegar dilator introduced into the graft, formed in a U shape to avoid an abrupt change in the diameter.

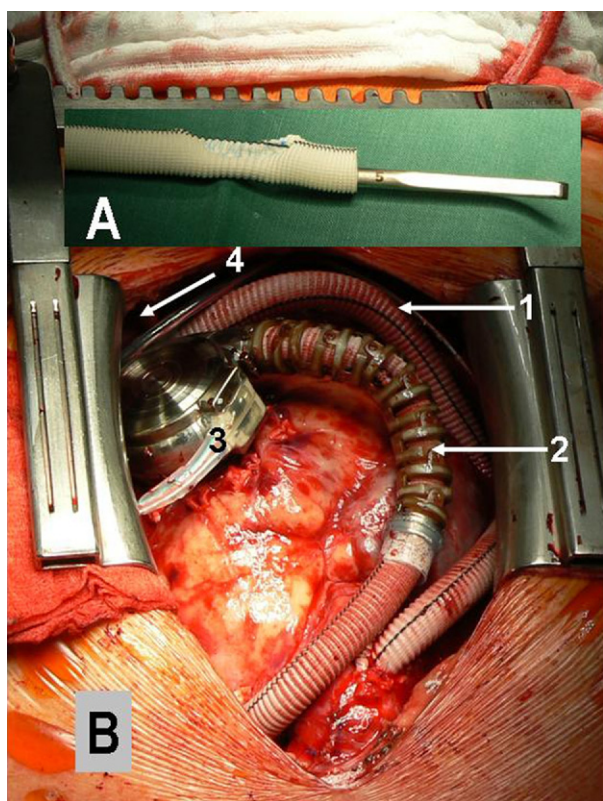


Figure 1 (A) The narrowing of the right ventricular assist device (RVAD) outflow graft is produced before surgery by suturing 3-cm of graft with 6-0 Prolene 2 cm from the outflow connector over a 5-mm Hegar dilator introduced into the graft. (B) Intraoperative view shows both pumps: 1, outflow graft of the left ventricular assist device (LVAD) connected to the ascending artery; 2, outflow graft of the RVAD connected to the pulmonary artery; 3, pump of the RVAD connected to the free wall of the right ventricle; 4, the pump of the LVAD is connected to the LV apex and is not seen on the figure.

Both pumps were intrapericardial. The drivelines crossed in the pericardium and emerged in the lower abdominal quadrant on the left (right pump) and right (left pump) side to allow long sub-cutaneous tunnelling. The RV improved after unloading and ejected up to 2 liters/min. The pump speeds were adjusted individually, depending on the patient's hemodynamic situation, to achieve flow of approximately 5 to 6 liters/min (left pump) and 3 to 4 liters/min (right pump). Anticoagulation was targeted to an international normalized ratio 3 to 3.5. Aspirin was used as determined by platelet function.

Of the 8 patients (1 woman; 2 redo case) (age, 57–63 years; body mass index, 17–32 kg/m²), 5 were at Interagency Registry for Mechanically Assisted Circulatory Support (INTERMACS) level II. Their postoperative courses were uneventful, and all patients were discharged home.

In 3 patients with HeartWare LVAD, the HeartWare RV pump was implanted secondarily after 13, 14, and 50 days of temporary RVAD support with the Levitronix pump (Levitronix, Waltham, MA). One patient died of multisystem organ failure, and another died of overflow pulmonary edema after RVAD implantation when the left pump stopped due to thrombosis. One patient survived. All 6 survivors are being evaluated for transplantation after rehabilitation.

An implantable centrifugal pump for RV support was investigated by Fukamachi et al³ in animal experiments. Frazier et al⁴ demonstrated feasibility of the total artificial heart using intracorporeal continuous-flow pumps in animals, but both ventricles were excised. In 1 LVAD patient with RV failure 2 weeks after surgery, Frazier et al implanted a Jarvik 2000 into the right atrium.⁴

The HeartWare pump is afterload sensitive. Thus an LVAD and RVAD set at the same speed will have markedly different flows due to the difference in pulmonary vascular resistance (PVR) and systemic vascular resistance (SVR). A crucial aspect allowing the safe use of 2 HeartWare pumps as an implantable BiVAD is the narrowing of the outflow graft of the RVAD, which causes elevation of the resistance and optimizes the flow/pressure relationship (Figure 2). Without narrowing, the right pump in a normal pulmonary resistance circuit would pump more volume than the left and result in overflow pulmonary edema.

The 2 options to avoid this situation are (1) reduction of the pump speed below recommended range, causing possible pump thrombosis or instability of the rotor, or (2) narrowing of the outflow graft, causing elevation of the total resistance for the pump and enabling the necessary volume to be pumped within the manufacturer's recommended pump speed. The necessary reduction of the cross section was investigated in vitro before surgery in a mock circulation with different diameters of the graft to achieve physiologic flow against low PVR, which is 20% of the SVR for which the pump was designed, with the optimal number of rotations per minute for the pump.

However, in patients with elevated PVR, especially if this elevation is not reversible, the narrowing should be of a lesser degree. In one such case, we downsized the graft to

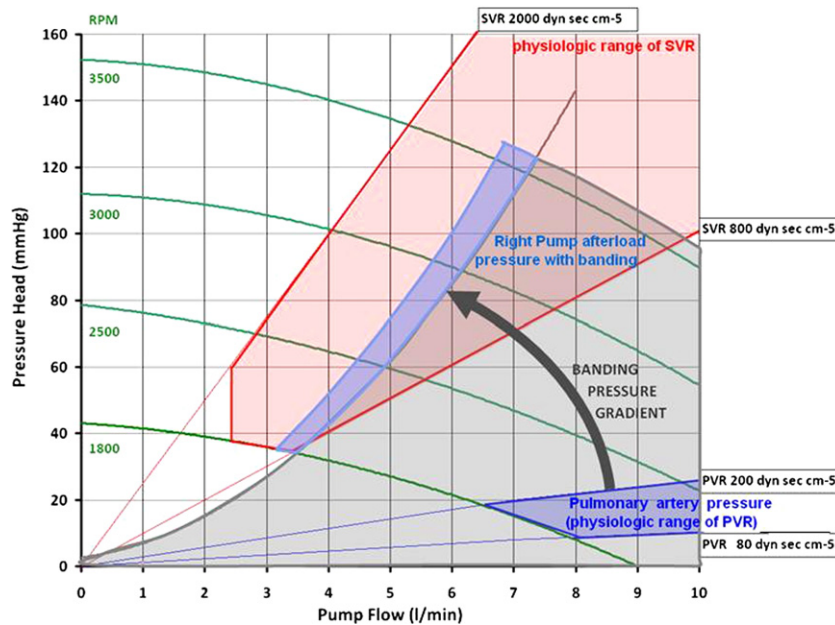


Figure 2 A performance diagram for HeartWare HVAD in vitro shows pressure head vs flow during constant speed. Transformation of the pressure-flow field of the pulmonary circulation into the pressure-flow field of the systemic circulation is achieved by narrowing of the outflow graft, which increases the pressure head and decreases the flow and thus adapts the right ventricular assist device (RVAD) pump to the low pressure pulmonary circulation. PVR, pulmonary vascular resistance; SVR, systemic vascular resistance.

a diameter of 7 mm. The grade of narrowing should be determined preoperatively, which may be challenging, especially if the PVR decreases during support. A system for adjustable outflow graft narrowing would be optimal.

Although our innovative system requires 2 controllers and 4 batteries, it is compact, with more flexible and thinner drivelines than the pneumatically driven total artificial heart. Long-term BiVAD support using the Heartware HVAD is feasible and warrants further investigational scrutiny.

Disclosure statement

The authors thank Anne Gale, Editor in the Life Sciences, for editorial assistance.

None of the authors has a financial relationship with a commercial entity that has an interest in the subject of the presented manuscript or other conflicts of interest to disclose.

Roland Hetzer, MD, PhD
Thomas Krabatsch, MD, PhD

Alexander Stepanenko, MD
Ewald Hennig, PhD
Evgenij V. Potapov, MD, PhD
*Deutsches Herzzentrum Berlin
Berlin, Germany*

References

1. Potapov EV, Loforte A, Weng Y, Jurmann M, Pasic M, Drews T, et al. Experience with over 1000 Implanted Ventricular Assist Devices. *J Card Surg* 2008;23:185-94.
2. Slaughter MS, Sobieski MA 2nd, Tamez D, et al. HeartWare miniature axial-flow ventricular assist device: design and initial feasibility test. *Tex Heart Inst J* 2009;36:12-6.
3. Fukamachi K, Saeed D, Massiello AL, et al. Development of DexAide right ventricular assist device: update II. *ASAIO J* 2008;54:589-93.
4. Frazier OH, Myers TJ, Gregoric I. Biventricular assistance with the Jarvik FlowMaker: a case report. *J Thorac Cardiovasc Surg* 2004;128:625-6.